

# CARDIOVASCULAR COMPLICATIONS RESULTING FROM TOPICAL LIDOCAINE APPLICATION

Feng Lin<sup>1</sup>, Wen-Han Chang<sup>1,2,3\*</sup>, Yu-Jang Su<sup>1,2</sup>, Cheng-Ho Tsai<sup>4</sup>

<sup>1</sup>Department of Emergency Medicine, Mackay Memorial Hospital, <sup>2</sup>Mackay Medicine, Nursing and Management College, <sup>3</sup>National Taipei University of Technology, and <sup>4</sup>Department of Cardiology, Mackay Memorial Hospital, Taipei, Taiwan.

## SUMMARY

Topical lidocaine is one of the most commonly used anesthetics in the emergency department (ED). The advantages of topical anesthesia include ease of application, minimal discomfort on administration, and rapid onset of anesthesia. Systemic toxic effects after topical lidocaine application are rare. We present a case of a man aged 48 years with no history of heart disease and no evidence of bradycardia in previous electrocardiograms. The patient had sprayed lidocaine solution on the glans of his penis before sex during the 2 weeks prior to admission. Cardiovascular adverse events occurred, including chest tightness and bradycardia. After 2 hours conservative treatment at our ED, his symptoms were alleviated. He was discharged from the ED without any medication. The case suggests that detailed patient histories are necessary for accurate diagnosis and that rapid diagnosis and implementation of treatment is necessary for successful patient outcomes in cases of cardiovascular complications resulting from topical lidocaine application. [International Journal of Gerontology 2008; 2(4): 229–232]

**Key Words:** adverse effects, bradycardia, lidocaine, topical administration

## Introduction

Skin penetration with a local anesthetic is a tried method of providing skin anesthesia and pain relief<sup>1</sup>. Several local anesthetic preparations are now available. Lidocaine formulated as a gel is one anesthetic that is widely used to provide skin anesthesia before venipuncture or incision. It can also reduce the pain associated with other procedures, such as lumbar puncture, intramuscular injection, and even circumcision<sup>2</sup>. Although many local anesthetics have not been approved by the United States' Food and Drug Administration for neuropathic pain conditions, several historical studies suggest that they can reduce the pain of postherpetic neuralgia<sup>3,4</sup>.

Another study found them to be of no benefit<sup>5</sup>. Topical application of lidocaine gel is not practical, however, for reducing sexual sensitivity.

Lidocaine is also available in a 5% patch formulation that has been approved for use in postherpetic neuralgia as the jelly form<sup>6,7</sup>. Lidocaine may also be used in a wide variety of other instances to reduce pain progressively, including painful polyneuropathy<sup>8</sup> and osteoarthritis<sup>9</sup>. In the emergency department (ED), local anesthetic agents are one of the most commonly used drugs. The amount of lidocaine actually absorbed is small and well below that which leads to systemic side effects. The safety margin is large and several patches can be used simultaneously, with no harmful effects. However, the central nervous system and the cardiovascular system are potentially particularly susceptible to the action of local anesthetics. The cardiovascular system is somewhat more resistant to the adverse effects of local anesthetics than the central nervous system.

There has been little reported on complications due to the topical use of lidocaine, especially on its use on



\*Correspondence to: Dr Wen-Han Chang, Department of Emergency Medicine, Mackay Memorial Hospital, 92, Section 2, Chung-Shan North Road, Taipei, Taiwan.

E-mail: branden888@gmail.com

Accepted: October 24, 2008

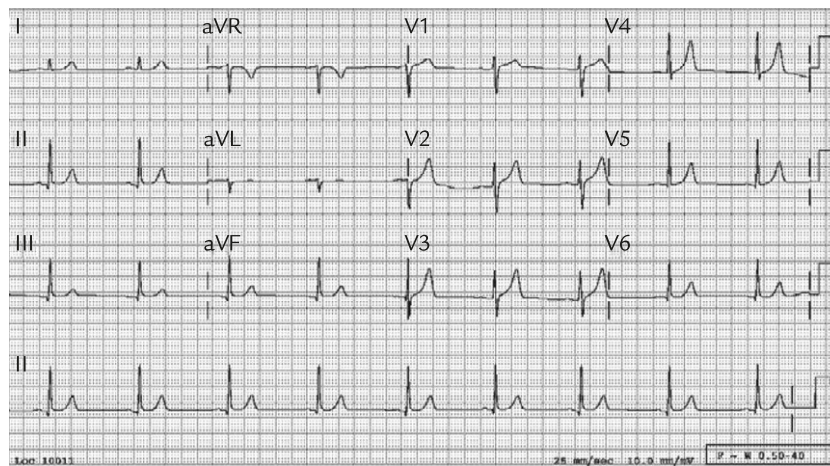


Figure. The presentation of patient's electrocardiogram after topical application of lidocaine.

the penis to maintain erection. We report a case of cardiac complications (chest tightness and bradycardia) arising from systemic toxicity after topical use of lidocaine on the penis before sexual intercourse. Emergency physicians should be on the alert for symptoms of lidocaine toxicity when there is a related history of topical lidocaine application.

## Case Report

The patient was a 48-year-old man who presented to the ED of Mackay Memorial Hospital in Taiwan. He complained of intermittent chest tightness without cold sweating or radiating pain. The tightness in his chest persisted for 2 days after spraying a large amount of lidocaine solution on his glans before sexual activity, which he had done during the preceding 2 weeks. Reviewing his past clinical history, there was no indication of hyperlipidemia, diabetes mellitus or heart disease. He had smoked half a pack of cigarettes daily for over 20 years. He denied any recent trauma.

At physical examination, the patient's vital signs were as follows: body temperature was 36.5°C; blood pressure was 135/72 mmHg; heart rate was 53 beats per minute; and the respiratory rate was 16 breaths per minute. The sizes of his bilateral pupils were the same at 3 mm in diameter with a light reflex. The conjunctiva was pink. The sclera was not icteric. There were no neck masses and the neck was supple. The lungs were clear on auscultation. Cardiac rhythm was regular, and there were no murmurs in the heart sounds. The abdomen was soft without palpable masses. The extremities were warm and circulation was good, and there was

no pitting edema. There was no erosion, swelling or pus seen on the glans.

We performed an electrocardiogram (ECG) and laboratory studies. The ECG revealed a small P wave and sinus bradycardia (Figure). Laboratory results were normal: troponin I was less than 0.10 ng/mL; creatine kinase MB was 2.6 U/L; creatine kinase was 109 IU/L; potassium was 4.4 mEq/L. The patient had no history of heart disease, and his previous ECGs had shown normal patterns. After excluding all of the most possible leading causes, we concluded that the complaints of chest tightness and the presentation of bradycardia on the ECG were most likely caused by the overuse of topical lidocaine, applied to the glans, which was then absorbed to produce general toxicity.

During a period of observation lasting several hours, the patient's condition stabilized. No drugs were given. Bradycardia still persisted on the ECG, but the patient ceased complaining of chest tightness. He was discharged 3 hours later. Before he left the ED, the patient was advised on the contraindications of lidocaine use. It was also suggested to this patient that he immediately return to the ED if he should again experience the adverse effects of lidocaine, including chest tightening and bradycardia. Even though this patient recovered without any medication, a cardiovascular follow-up visit was arranged.

## Discussion

Lidocaine is one of the most widely used local anesthetic agents in the ED. Topical anesthetics, unlike injectable anesthetics, can be applied painlessly and can provide

sufficient pain control to maintain patient comfort throughout many procedures. Use of topical lidocaine is considered relatively safe<sup>10–17</sup>; but some instances of adverse events have been reported. Amitai et al.<sup>18</sup> reported a fatal overdose in a boy aged 13 months following ingestion of an oral lidocaine preparation. Upon admission, the serum lidocaine level of the boy was found to be 19.5 µg/mL. The boy was treated with mechanical ventilation and brain resuscitation but did not regain consciousness, and died approximately 50 days after overdose.

Promisloff and DuPont<sup>19</sup> reported delayed hypotension and tachycardia with cardiovascular collapse, and adult respiratory distress syndrome following the administration of less than 30 mL of 1% lidocaine solution for topical anesthesia prior to fiberoptic bronchoscopy.

Mofenson et al.<sup>20</sup> reported that a male infant aged 11 months developed seizures and had a plasma lidocaine concentration of 10 µg/mL, following the application of 2% viscous lidocaine to his gums 5–6 times daily for a week.

Therapeutic levels of lidocaine are 1–5 µg/mL. Toxicity may sometimes occur at therapeutic drug levels. Serious poisoning may occur at lidocaine levels above 5 µg/mL. Lidocaine toxicity affects many systems<sup>21–24</sup>. In the cardiovascular system, it depresses cardiac conduction and contractility, causing dysrhythmias (sinus bradycardia, atrioventricular junctional or ventricular bradycardia, second- or third-degree heart block, asystole, and rarely ventricular tachycardia or fibrillation resulting from re-entrant mechanisms)<sup>10,25–27</sup>.

In our case, the patient, who had no history of heart attack, was healthy prior to this incident. He had only once been hospitalized because of a left inguinal hernia, and had shown heart stress tightness and abnormal sinus rhythm on the ECG, with a heart rate of around 53 beats per minute. We presumed that the cause of the cardiovascular episode in this patient was the topical application of lidocaine to his penis, which was related to the adverse effects, although no data was supplied from laboratory studies. In previous reports, severe bradycardia and even cardiac arrest have been found in healthy patients following neuraxial anesthesia, with a reported incidence of cardiac arrest of 6.4 per 10,000 patients associated with spinal anesthesia. However, there are no studies reporting only on the incidence of complications resulting from topical anesthesia. In such cases, prompt diagnosis, immediate cardiopulmonary resuscitation and aggressive vasopressor therapy

with epinephrine (adrenaline) are required<sup>28</sup>. After reviewing this case, we speculate that the adverse effects caused by topical use of lidocaine are not as serious as those caused by systemic use. Many previous reports have indicated that lidocaine dermal absorption takes about 3.5 hours (ranging from 2.0 to 5.9 hours), and it is 95% metabolized by the liver; less than 10% is excreted unchanged in the urine and the elimination half-life is 1.5–2 hours. The treatment of bradycardia related to lidocaine toxicity is essentially supportive. The airway should be maintained and oxygen is necessary in symptomatic bradycardia, while monitoring of blood pressure and continuous ECG is mandatory in the ED. Recovery from bradycardia is usually automatic without aggressive treatment, but if persistent hypotension or relatively unstable signs are exhibited, atropine and cardiac pacing are indicated<sup>29–33</sup>. When bradycardia occurs, causing hemodynamic disturbances, only treatment with atropine is indicated. When cardiac arrest occurs, cardiopulmonary resuscitation must be performed. The main treatments include oxygen, sodium bicarbonate, adrenaline, calcium, and perhaps glucagon. This must be continued until symptoms resolve<sup>34</sup>.

In conclusion, this case highlights the fact that emergency physicians should consider toxicity as a possible diagnosis when patients present with cardiac symptoms, especially with prior administration of topical anesthetic agents. Topical lidocaine toxicity is very rare, but that does not mean it is not possible. The importance of detailed history taking is the key point to be taken from this case. Rapid and accurate diagnosis results in the avoidance of unwarranted treatment and undue distress to the patient. In the case of an inexact diagnosis, medical resources could be wasted on needless procedures and unnecessary medication.

## References

1. McClean G. Topical analgesic agents. *Clin Geriatr Med* 2008; 24: 299–312.
2. Carter GT, Galer BS. Advances in the management of neuropathic pain. *Phys Med Rehabil Clin N Am* 2001; 12: 447–59.
3. Attal N, Brasseur L, Chauvin M, Bouhassira D. Effects of single and repeated applications of a eutectic mixture of local anaesthetics (EMLA) cream on spontaneous and evoked pain in post-herpetic neuralgia. *Pain* 1999; 81: 203–9.

4. Litman SJ, Vitkun SA, Poppers PJ. Use of EMLA cream in the treatment of post-herpetic neuralgia. *J Clin Anesth* 1996; 8: 54–7.
5. Lycka BA, Watson CP, Nevin K. EMLA cream for the treatment of pain caused by post-herpetic neuralgia: a double-blind, placebo-controlled study [abstract]. In: Proceedings of the Annual Meeting of the American Pain Society. Glenview, IL: American Pain Society, 1996; A111.
6. Rowbotham MC, Davies PS, Verkempinck C, Galer BS. Lidocaine patch: double-blind controlled study of a new treatment method for post-herpetic neuralgia. *Pain* 1996; 65: 39–44.
7. Galer BS, Rowbotham MC, Perander J, Friedman E. Topical lidocaine patch relieves postherpetic neuralgia more effectively than a vehicle topical patch: results of an enriched enrollment study. *Pain* 1999; 80: 533–8.
8. Herrmann DN, Barbano RL, Hart-Gouleau S, Pennella-Vaughan J, Dworkin RH. An open-label study of the lidocaine patch 5% in painful idiopathic sensory polyneuropathy. *Pain Med* 2005; 6: 379–84.
9. Gammaitoni AR, Galer BS, Onawola R, Jensen MP, Argoff CE. Lidocaine patch 5% and its positive impact on pain qualities in osteoarthritis: results of a pilot 2-week, open-label study using the Neuropathic Pain Scale. *Curr Med Res Opin* 2004; 20 (Suppl): S13–9.
10. Eledjam JJ, Gros T, Viel E, Mazoit JX, Bassoul B. Ropivacaine overdose and systemic toxicity. *Anaesth Intensive Care* 2000; 28: 705–7.
11. Touma S, Jackson JB. Lidocaine and prilocaine toxicity in a patient receiving treatment for mollusca contagiosa. *J Am Acad Dermatol* 2001; 44 (2 Suppl): 399–400.
12. Alfano SN, Leicht MJ, Skiendzielewski JJ. Lidocaine toxicity following subcutaneous administration. *Ann Emerg Med* 1984; 13: 465–7.
13. Saima S, Echizen H, Yoshimoto K, Ishizaki T. Negligible removal of lidocaine during arteriovenous hemofiltration. *Ther Drug Monit* 1990; 12: 154–6.
14. Palmisano JM, Meliones JN, Crowley DC, Martin JM, Truman KH, Krauzowicz BA, et al. Lidocaine toxicity after subcutaneous infiltration in children undergoing cardiac catheterization. *Am J Cardiol* 1991; 67: 647–8.
15. Jackson T, McLure HA. Pharmacology of local anesthetics. *Ophthalmol Clin North Am* 2006; 19: 155–61.
16. Chang YY, Ho CM, Tsai SK. Cardiac arrest after intra-urethral administration of lidocaine. *J Formos Med Assoc* 2005; 104: 605–6.
17. Parker JF, Vats A, Bauer G. EMLA toxicity after application for allergy skin testing. *Pediatrics* 2004; 113: 410–1.
18. Amitai Y, Whitesell L, Lovejoy FH Jr. Death following accidental lidocaine overdose in a child. *N Engl J Med* 1986; 314: 182–3.
19. Promisloff RA, DuPont DC. Death from ARDS and cardiovascular collapse following lidocaine administration. *Chest* 1983; 83: 585.
20. Mofenson HC, Caraccio TR, Miller H, Greensher J. Lidocaine toxicity from topical mucosal application. With a review of the clinical pharmacology of lidocaine. *Clin Pediatr (Phila)* 1983; 22: 190–2.
21. Tei Y, Morita T, Shishido H, Inoue S. Lidocaine intoxication at very small doses in terminally ill cancer patients. *J Pain Symptom Manage* 2005; 30: 6–7.
22. Perney P, Blanc F, Mourad G, Blayac JP, Hillaire-Buys D. Transitory ataxia related to topically administered lidocaine. *Ann Pharmacother* 2004; 38: 828–30.
23. Smith M, Wolfram W, Rose R. Toxicity—seizures in an infant caused by (or related to) oral viscous lidocaine use. *J Emerg Med* 1992; 10: 587–90.
24. Nelson LS, Hoffman RS. Intrathecal injection: unusual complication of trigger-point injection therapy. *Ann Emerg Med* 1998; 32: 506–8.
25. Rosenberg PH, Veering BT, Urmey WF. Maximum recommended doses of local anesthetics: a multifactorial concept. *Reg Anesth Pain Med* 2004; 29: 564–75; discussion 524.
26. Donald MJ, Derbyshire S. Lignocaine toxicity: a complication of local anaesthesia administered in the community. *Emerg Med J* 2004; 21: 249–50.
27. Sawyer RJ, von Schroeder H. Temporary bilateral blindness after acute lidocaine toxicity. *Anesth Analg* 2002; 95: 224–6.
28. Faccenda KA, Finucane BT. Complications of regional anaesthesia: incidence and prevention. *Drug Saf* 2001; 24: 413–42.
29. Olkkola KT, Isohanni MH, Hamunen K, Neuvonen PJ. The effect of erythromycin and flvoxamine on the pharmacokinetics of intravenous lidocaine. *Anesth Analg* 2005; 100: 1352–6.
30. Kudo K, Nishida N, Kiyoshima A, Ikeda N. A fatal case of poisoning by lidocaine overdose—analysis of lidocaine in formalin-fixed tissues: a case report. *Med Sci Law* 2004; 44: 266–71.
31. Zuberi BF, Shaikh MR, Jatoti NU, Shaikh WM. Lidocaine toxicity in a student undergoing upper gastrointestinal endoscopy. *Gut* 2000; 46: 435.
32. Lie RL, Vermeer BJ, Edelbroek PM. Severe lidocaine intoxication by cutaneous absorption. *J Am Acad Dermatol* 1990; 23: 1026–8.
33. Mehra P, Caiazzo A, Maloney P. Lidocaine toxicity. *Anesth Prog* 1998; 45: 38–41.
34. d’Athis F. [How should a toxic accident be treated?]. *Ann Fr Anesth Reanim* 1988; 7: 227–32. [In French]